


HEB

A Comprehensive Review on Prosthetic Management of Nasal Defects

JOPD

Dr. Anandkumar GPatil*(MDS Prosthodontics) patilprostho@yahoo.co.in***Dr. Sayali D. Mardolkar***(Post Graduate Student, Dept of Prosthodontics) (sayali.mardolkar@gmail.com)***Dr. AbijitPatil***(MDS Prosthodontics)dr.abhijitpatil85@gamil.com***Dr. PrashantKarni** prashantkarni@yahoo.co.in*Email ID - serviceheb@gmail.com, sayali.mardolkar@gmail.com***ABSTRACT:**

Restoration of facial defects or nasal defects is a major challenge for any clinician and can be accomplished either surgically, prosthetically or through a combination of both. Esthetic reestablishment is the most important purpose in reconstruction of maxillofacial defects. This review article describes in detail the steps to rehabilitate a patient with nasal defects starting from patient evaluation and clinical examination, impression making procedures, the clinical and laboratory steps and the retention of such prosthesis.

Access this Article Online	Quick Response Code: 
Website: http://heb-nic.in/jopd	
Received on 03/02/2020	
Accepted on 06/03/2020 © HEB All rights reserved	

INTRODUCTION

Facial deformities or nasal deformities as a result of trauma, tumors, infection, ablation surgery or any congenital defect affects patient's appearance, function, psychological depression, and impaired social life.

Restoration of facial defects or nasal defects can be accomplished either surgically, prosthetically or through a combination of both. Esthetic reestablishment is the most important purpose in reconstruction of maxillofacial defects.¹ The goals of nasal reconstruction are to achieve refined aesthetic outcomes while preserving nasal function.

The method of rehabilitation depends upon the site, size, etiology, severity, age, and the patient's wishes. However, age, general medical condition of the patient, radiation therapy, anatomic complexity, possibility of recurrence, appearance of the area to be rehabilitated, complexity of the surgical procedure, and the patient's refusal to undergo further surgery may contraindicate surgical reconstruction, resulting in a major defect.^{2,3}

For larger defects with extensive anatomical loss, when surgical approach is not a feasible option, the prosthetic rehabilitation is considered the best choice. Prosthetic rehabilitation of such patients then has considerable advantages that a prosthesis offers the clinician and the patient the means to observe the healing wound for recurrence of the disease, esthetic improvement, technical simplicity, and inexpensive care. Pre-surgical records like photographs, mounted intra-oral casts and facial cast if available, could facilitate the fabrication of the prosthesis.⁴

This article describes the types of nasal defects, analysis of defect, steps for fabrication and construction of a large nasal prosthesis using the available materials.

Nasal defects may be caused by trauma, due to tumours, infections, auto immune diseases, or may be a result of congenital anomalies.⁵

ANALYSIS OF THE NASAL DEFECT

Before decisions about nasal reconstruction can be made, it is important to perform a detailed analysis of the defect for shape, contour, anatomy of nasal bridge, nasolabial angle symmetry, upper lip mobility, healed tissue bed, available favourable and unfavourable hard and soft tissue undercuts, composite defects involving surrounding tissues of maxilla, oral and orbital cavity. Prosthodontist can suggest changes during nasal surgery for better prosthodontic prognosis. The depth and location of the defect has a direct bearing on the options available for reconstruction.⁶

Patients with poor vision manual dexterity i.e. who are incapable to manage and maintain the prostheses are poor choices for prosthetic rehabilitation. Once the nasal analysis is complete, the surgeon and prosthodontist should provide outline of a planned procedures, alternatives to reconstruction to the

patient. At this point is important to incorporate the patient's medical status, risks for complications, expectations, and desires as it relates to the method of reconstruction

PREPARATION OF THE PATIENT

Patients are to be educated about the choice of prosthesis and retentive methods to be used. They should be prepared to learn about their prostheses like about its attachment, removal and cleaning methods. They are to be educated about the limited life span of the prostheses. ⁶

In the history of anaplastology a wide range of materials have been used such as porcelain, natural rubber, gelatin and latex but the most commonly used materials are methacrylates and silicones, but none of them fulfill all the requirements for a satisfactory prosthesis. ⁷

IMPRESSIONS IN NASAL DEFECTS

Proper impression making and recording of all the anatomical landmarks and favorable undercuts is of utmost importance to fabricate a prosthesis that is functionally and esthetically acceptable. Various materials like elastomers, alginate in conjunction with impression compound and dental plaster may be used to make the impression

n of the facial defect.

Steps in impression making:

1. Drape the patient and apply petroleum jelly to the defect and surrounding areas to avoid the impression material from sticking to the skin, eyebrows and eyelashes.
2. Moist gauze or cotton should be placed in the unfavorable undercuts to facilitate easy removal of the impression. Care needs to be taken not to block the desirable undercuts as they are a source of mechanical retention for the prosthesis which is to be fabricated.
3. Impression can be made of only the nasal defect or of the entire face depending on the extensions of the planned prosthesis. (figure 1, 2)
4. Impression can be made of the defect and adjacent tissues using irreversible hydrocolloid impression material. Paper clips can be attached on the wet surface of impression material and reinforced with plaster.⁸

Alternatively the boundary for the external nasal impression may be outlined on the face using softened modeling plastic impression compound to confine the impression material. A plastic tube is then placed in the nostrils or mouth to allow the patient to breathe.²

An impression technique was reported for nasal prostheses that places pressure in the superior regions of the nasolabial sulci.⁹

5. Recently developed impression methods include use of intraoral scanners or CT scan of the face which prevent discomfort to the patient and also prevent the distortion of tissue and defect margins during impression making.¹⁰

FABRICATION OF WORKING CAST AND WAX PATTERN

1. The impression may be boxed using modelling wax and carefully poured in dental stone with appropriate water powder ratio and a definitive undamaged cast may be obtained without any voids.¹¹
2. A wax pattern is fabricated on this cast using a donor impression or arbitrarily maintaining the basic external anatomy of the nose or in some cases the pre-operative photographs may also be used to fabricate the same. (figure 3, 4)
3. The margins of the wax pattern should be kept feather edge so that they merge properly with the patient's skin and there isn't any unnecessary trimming of the final prosthesis.
4. A hollow wax pattern may also be fabricated to reduce the weight of the final prosthesis.¹²
5. The wax pattern is then carefully tried on the patient to see for the adaptability of the margins, esthetics and patient comfort.
6. Wax patterns may also be prepared using the SLS technique which provide precise replicas of the patient's anatomy.¹³

PROCESSING OF PROSTHESIS

1. The wax pattern may be processed in the conventional manner by investing and flasking or the wax pattern may be scanned again and the prosthesis may be fabricated by 3D printing.

The wax prosthesis is invested and the wax is eliminated. A mold is prepared and packed. The wax form is processed in heat-polymerizing clear acrylic resin. Room temperature vulcanising silicones (RTV) or heat vulcanised silicones (HTV) can be used for the same

For heat-polymerizing clear acrylic resin, an oil-based paint is mixed on a ceramic slab to match the skin color of the patient. The paint was then incorporated into the heat-polymerizing acrylic resin monomer, and polymer powder is mixed. The material is polymerized in a water bath at 74°C for 8 hours.²

Whereas for RTV and HTV, intrinsic stains may be added for the measured quantity of the base and catalyst of the silicone material and compared with the patient's skin colour for precise shade matching.

The processing temperature for HTV is 180°C- 220°C¹⁴ for about 30 min under pressure using metal molds whereas RTVs requires heating the material at 150°C for a time, possibly an hour.¹⁵

2. The prosthesis is recovered after polymerization and rinsed with water to eliminate all residues.

3. Feather-edged borders need to be developed so that the prosthesis merges with the skin and surrounding tissues. This may be done using an acrylic bur or silicone polishing bur. The prosthesis is then tried on the patients face and appropriate adjustments are made.

RETENTION OF PROSTHESIS

Retention is a major factor for the long-term success of facial prostheses. Common methods for anchoring prosthesis are⁷

1. Anatomical anchorage is done to already existing anatomical structures for example: an undercut area in the defect.

Partial or complete removal of nasal tissue can create a variety of anatomic possibilities for retention due to the sub defect spaces provided by the nasal cavity and maxillary sinus.

Lateral nasal defects can be similarly treated with prosthesis projections, making use of gravitational forces and anatomic spaces for retention. If the maxillary sinus is exposed by the lateral resection, additional retentive space can be used.

Total excision of the nose may offer less opportunity for tissue retention if the maxillary sinuses are not exposed. Occasionally, adequate external tissue undercuts will allow the prosthesis to be retained without adhesives.

2. Mechanical anchorage is done with the help of spectacle frames, hair bands, magnets etc. Adhesives are used for chemical anchorage but these have the disadvantage of irritation, perspiration and movement that compromises the bond. (figure 5,6)
3. Surgical anchorage commonly uses implants. Implants at cellular level can be retained by bio integration, fibro-osseous integration or Osseo integration.¹⁶ The most reliable anchorage is by Osseo integration, as the implant gets structurally and functionally integrated in to the bone.

In metals titanium is the best choice of material for implanting prostheses. Implants made up of titanium and titanium alloys, aluminum oxide ceramics, tantalum stainless steel, cobalt and nickel-based alloys shows direct contact with the bone. Most importantly there is osteoblastic activity.¹⁴

A minimum of two implants may be placed, positioned in each lateral rounded nasal eminence. Because the implants are not evenly placed and are located in different parts of the defect, the abutments may be connected by a bar.¹⁷Zygomatic implants have been used in an unorthodox manner.¹⁸

CONCLUSION

Rehabilitation of facial defects relating to any region of the face is very important not only from a functional point of view, but mostly for esthetic purposes. Maxillofacial prosthesis have shown to tremendously affect the quality of life of the patient. Simple available materials can be extremely helpful in the fabrication of maxillofacial prostheses if CAD-CAM or maxillo-facial implants are not accessible.

These can be extremely cost effective, conservative and without side effects. But such methods require artistic skills of the operator and are technique sensitive and manual labour which is reduced when the digital workflow is considered. However, a thorough patient evaluation is always mandatory, to determine the quality of restorations and the patient preferences.

REFERENCE

1. Negahdari R, Pournasrollah A, Bohlouli S, SighariDeljavan A. Rehabilitation of a partial nasal defect with facial prosthesis: a case report. *J Dent Res Dent Clin Dent Prospects*. 2014;8(4):256–259. doi:10.5681/joddd.2014.046
2. Rodrigues SJ, Saldanha S. Prosthetic rehabilitation of a patient after partial maxillectomy: A clinical report. *ContempClin Dent*. 2011;2:355–358. doi:10.4103/0976-237X.91803
3. Comprehensive Management of Head and Neck Tumors, 2nd ed. In. Thawley SE, Batsaki JG, Lindberg RD, Panje WR, Donley S, editors. St Louis: Elsevier; 1998 p.526-7
4. Ahmed B, Butt AM, Hussain M, Amin M, Yazdanie N. Rehabilitation of nose using silicone based maxillofacial prosthesis. *J Coll Physicians Surg Pak*. 2010 Jan 1;20:65-7.
5. Patton TJ, Thomas JR. Classification and etiology of nasal defects. *Facial Plastic Surgery*. 1984;2:9-15.
6. Austin GK, Shockley WW. Reconstruction of nasal defects: contemporary approaches. *CurrOpinOtolaryngol Head Neck Surg*. 2016;24:453–460. doi:10.1097/MOO.0000000000000295
7. Karthikeyan I. A review on prosthetic rehabilitation of maxillofacial region. *Anaplastology*. 2014;3:2161-1173.
8. Shetty, Sanath, et al. "Nasal reconstruction with silicone using customised impression technique." *Journal of Indian Prosthodontic Society* 18.1 (2018): 68-71.
9. Shifman A. Selective-pressure impression technique for nasal prostheses. *The Journal of prosthetic dentistry*. 1987 Sep 1;58(3):349-51.
10. Chaturvedi S, Bhagat T, Verma AK, Gurumurthy V, Ali M, Vadhvani P, Chaturvedi M. Rehabilitation of Nose following Chemical Burn Using CAD/CAM Made Substructure for Implant Retained Nasal Prosthesis: A Clinical Report. *Case reports in dentistry*. 2017;2017.
11. Vyas A, Maru K, Bali SK, Jain S, Shukla J, Kataria N. A new simplified beading and boxing procedure for elastic impression. *J Indian Prosthodont Soc*. 2011;11:52–54. doi:10.1007/s13191-011-0063-z
12. Kumar S, Savadi RC, Srinivasan M, Satheesh P. Innovative technique for fabrication of hand prosthesis. *The Journal of Indian Prosthodontic Society*. 2009 Jul 1;9:151.

13. Wu G, Zhou B, Bi Y, Zhao Y. Selective laser sintering technology for customized fabrication of facial prostheses. *The Journal of prosthetic dentistry*. 2008 Jul 1;100:56-60.
14. Anusavice Kenneth J, Phillips' science of dental materials 2009 11th ed St. Louis Saunders Elsevier
15. Mitra A, Choudhary S, Garg H, HG J. Maxillofacial prosthetic materials-an inclination towards silicones. *Journal of clinical and diagnostic research: JCDR*. 2014 Dec;8:ZE08.
16. de Jong M, de Cubber J, de Roeck F, Lethaus B, Buurman D, et al. (2011) [The art of facial prosthetics]. *Ned Tijdschr Geneesk* 155: A3967.
17. Gurjar R, Kumar MV S, Rao H, Sharma A, Bhansali S. Retentive Aids in Maxillofacial Prosthodontics-A Review. *International Journal of Contemporary Dentistry*. 2011 Apr 7;2
18. Bowden JR, Flood TR, Downie IP. Zygomatic implants for retention of nasal prostheses after rhinectomy. *Brit J of O and Maxfac Surg*. 2006 Feb 1;44:54-6.

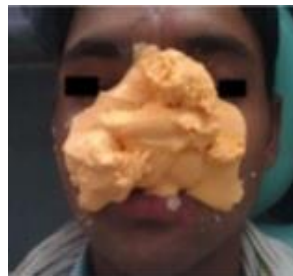

Figure 1: impression of the nasal defect made with irreversible hydrocolloid



Figure 2: impression of face made with alginate and covered in plaster

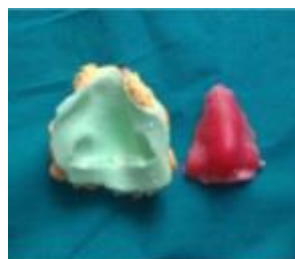

Figure 3. Donor nose impression and wax pattern of nose

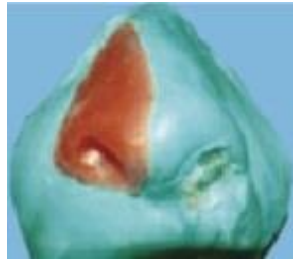


Figure 4: wax pattern made according to the anatomy of the patients nose

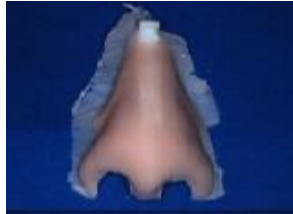


Figure 5: Nasal Prosthesis

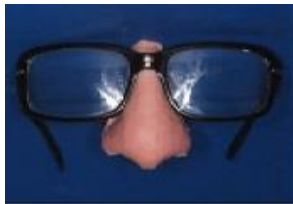

Figure 6: Retention of Nasal Prosthesis with spectacles